

PLATE XIII

- Fig. 1. Viscera of the holotype of *B. nigricans* (No. 1, std. 1. 208 mm). Large, thin, testicular lobes. Relatively short pyloric caeca.
- Fig. 2. Viscera of *B. nigricans* (No. 2, std. 1. 214 mm). Small, thin, testicular lobes. Relatively short pyloric caeca.
- Fig. 3. Viscera of the holotype of *B. macrophthalmus* (std. 1. 203 mm). Large, thick, testicular lobes. Relatively long pyloric caeca.

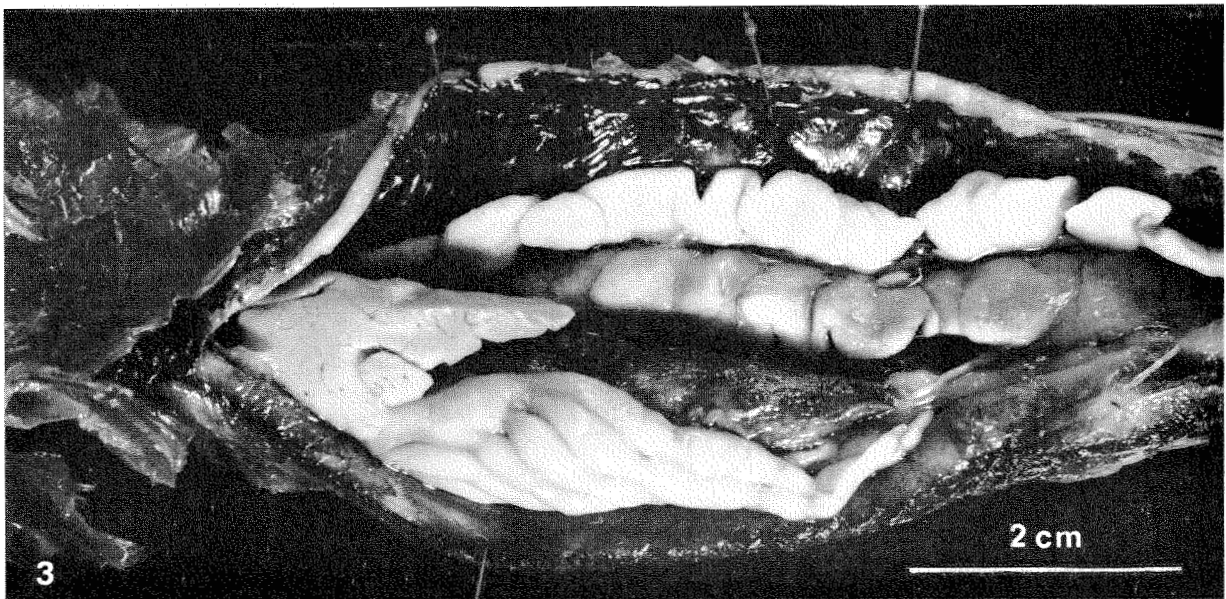
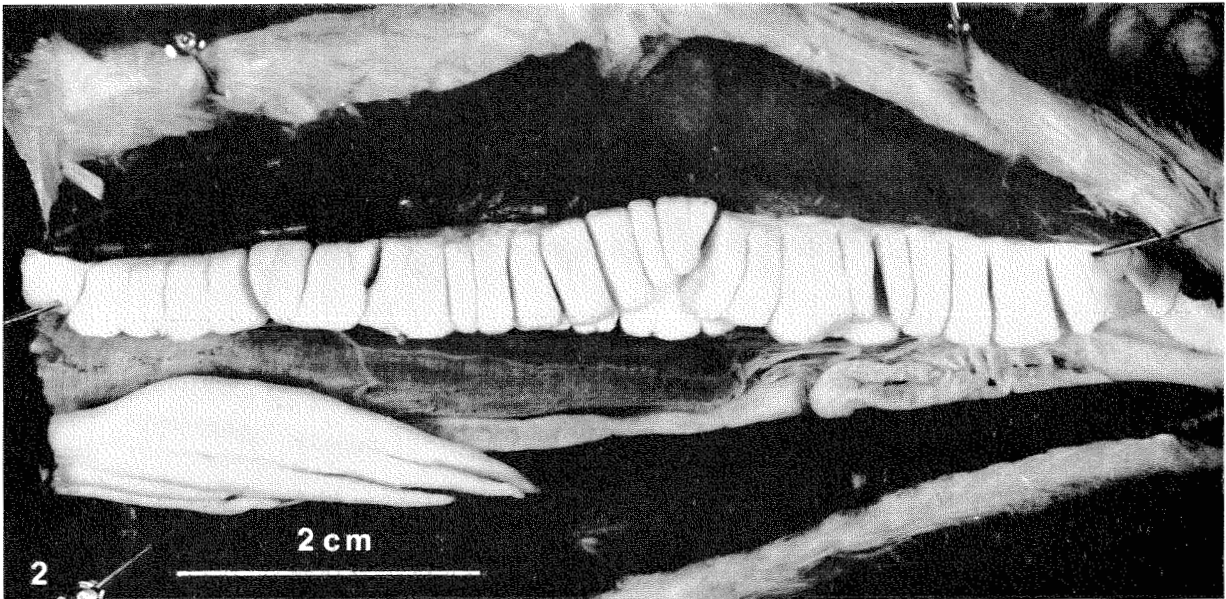
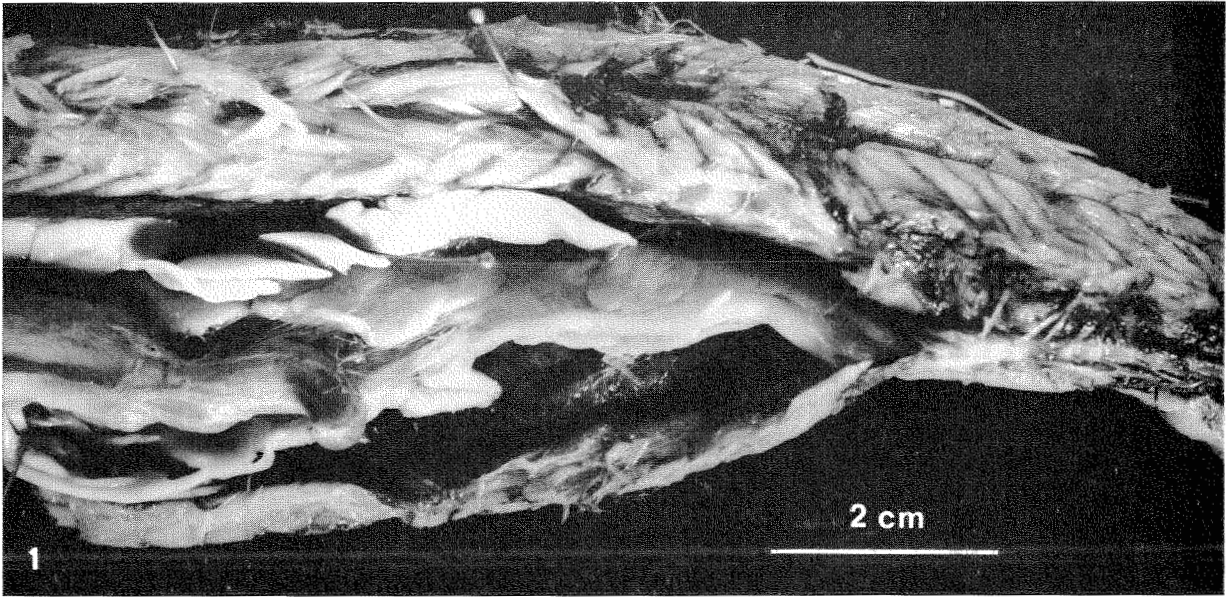


PLATE XIV

- Fig. 1. Viscera of *B. nigricans* (No. 4, std. l. 317 mm). Egg diameter from 0.1-2.4 mm. Relatively short pyloric caeca.
- Fig. 2. Radiograph of the caudal part of *B. nigricans* (No. 3, std. l. 340 mm). Only the two preural vertebral centra are not ossified.
- Fig. 3. Radiograph of the caudal part of *B. nigricans* (No. 5, std. l. 220 mm). No ossified vertebral centra.

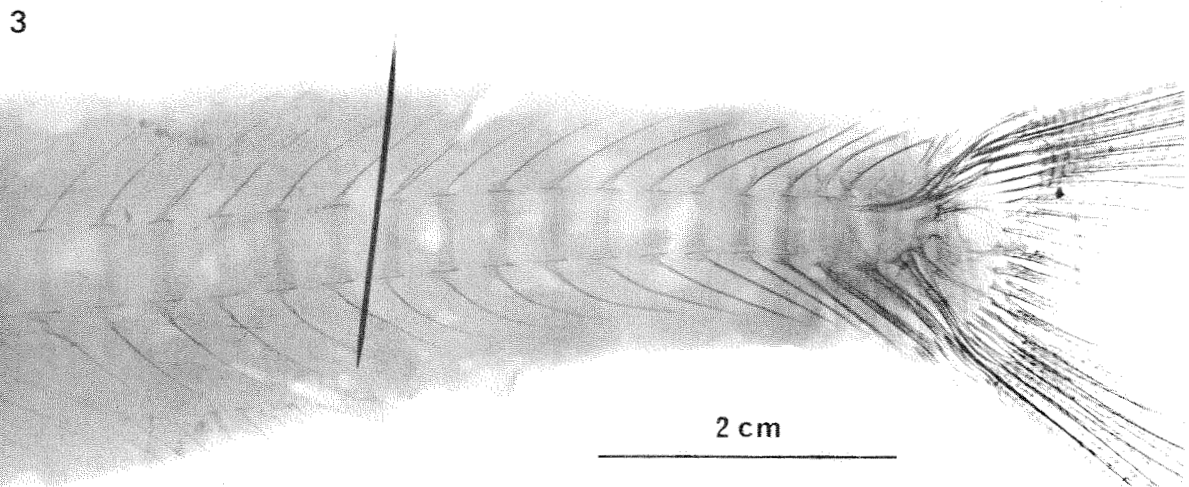
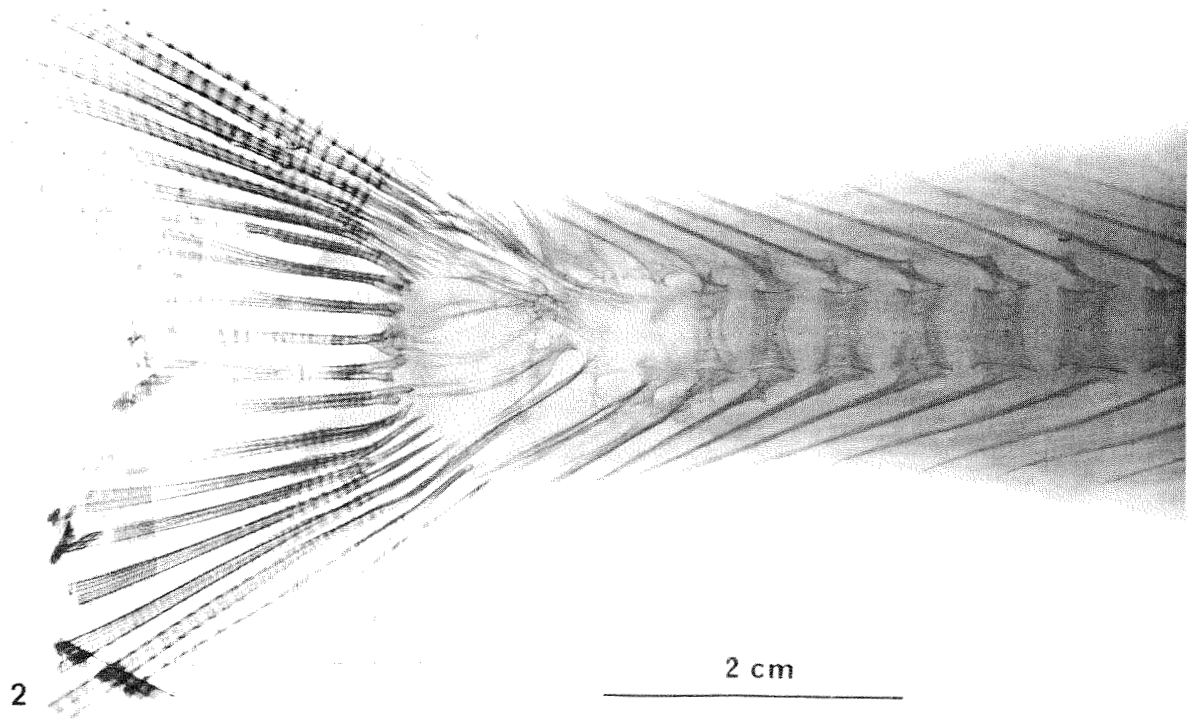

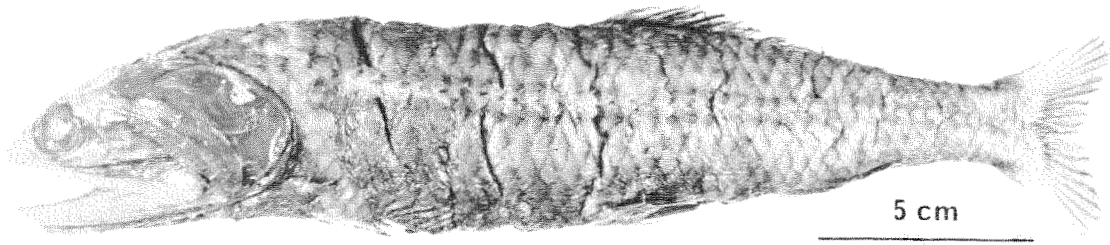


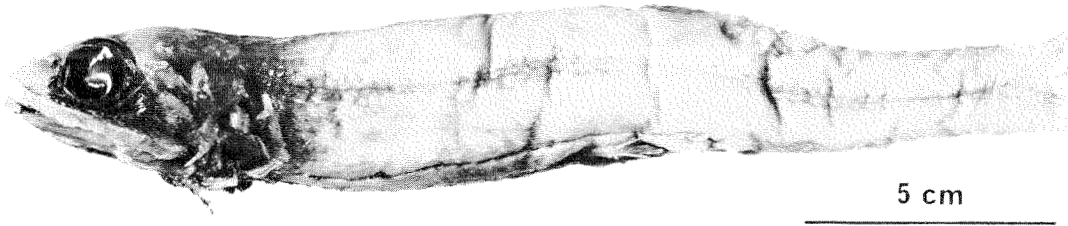
PLATE XV

- Fig. 1. *B. nigricans* (No. 10, std. 1. 234 mm).
Fig. 2. Holotype of *B. macrophthalmus* (std. 1. 203 mm).
Fig. 3. Cleared and stained left pectoral girdle seen from the inside. *B. nigricans* (No. 4, std. 1. 317 mm). c: coracoid, cl: cleitrum, mc: mesocoracoid, pcl: postcleitrum, pf: pectoral fin, sc: scapula.

1



2



3

